

Maxillary Midline Diastema – Aetiology And Orthodontic Treatment- Clinical Review

Muhamad Abu-Hussein^{*}, Nezar Watted^{**}

^{*} University Of Naples Federic II, Naples, Italy, Department Of Pediatric Dentistry, University Of Athens, Athens, Greece

^{**} University Hospital Of Würzburg Clinics And Policlinics For Dental, Oral And Maxillofacial Diseases Of The Bavarian Julius-Maximilian-University Wuerzburg, Germany And Department Of Orthodontics, Arab American University, Jenin, Palestine

Abstract: Maxillary midline diastema is a common esthetic problem in mixed and permanent dentition. The space can occur either as a transient malocclusion or created by developmental, pathological or iatrogenic factors. Many innovative therapies are available from restorative procedures such as composite build-up to surgery (frenectomies) and Orthodontics is available. Treatment depends upon the correct diagnosis of its etiology and early intervention relevant to the specific etiology. The aim of this article is to review the possible aetiology and management options which will help the clinician to diagnose, intercept and to take effective action to correct the midline diastema.

Keywords: Diastema, orthodontic treatment, retention, relapse, hypertrophic frenum

I. Introduction

Diastema, which means interval in Greek, is a gap or space between two or more consecutive teeth. It occurs more frequently in the median plane of the maxillary arch between the two central incisors and hence called the median, central or midline diastema.[1,2] Maxillary midline diastemas are an aesthetic concern for many patients and their parents. The diastema seen in many children as part of normal development in the mixed dentition, disappears naturally in most cases as dental development proceeds. It may however persist either because of its width or other associated factors. If it is to be closed satisfactorily by orthodontics an understanding of the aetiology is essential.[1,2,3,4]

Angle (1907) described the dental midline diastema as a rather common form of incomplete occlusion characterized by a space between the maxillary and – less frequent mandibular central incisors. He also recognized the functional and esthetic implications of the midline diastema. He stated that the interdental diastema "always creates an unpleasant appearance and interferes with speech depending on its width".[5] Similarly, Andrews (1972) in his classical article "The six keys to normal occlusion" supported, in the fifth principle, the view that interdental diastemas should not exist and that all contact areas should be tight, so that the patient has "straight and attractive teeth, as well as a correct overall dental occlusion".[6]

Numerous studies have investigated the frequency/prevalence of diastema. Consequently, there was a wide range of findings from 1.6% to 25.4% in adults and an even greater range in groups of young people. Differences in epidemiological study findings may be attributed to the increased number of factors contributing to midline diastema, to the definitions used to explain its presence and to gender and race differences in the distribution of the hereditary feature in question.[1,2,3]

Moyers (1988)[7] studied 82 patients that presented maxillary midline diastema and reported the following causes:

- a) imperfect fusion at midline of premaxilla (32.9%),
- b) enlarged or malposed upper labial frenum (24.4%) (Fig. 01),
- c) midline diastema as part of normal growth (23.2%),
- d) congenitally missing lateral incisors (11%) (Fig. 02a-c),
- e) supernumerary teeth at the midline (3.7%) (Fig. 03a-c),
- f) unusually small teeth (2.4%) (Fig. 04), and

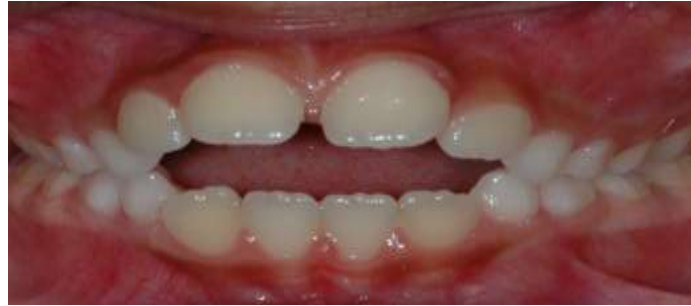

Fig.01: Diastema with abnormal Fraenum

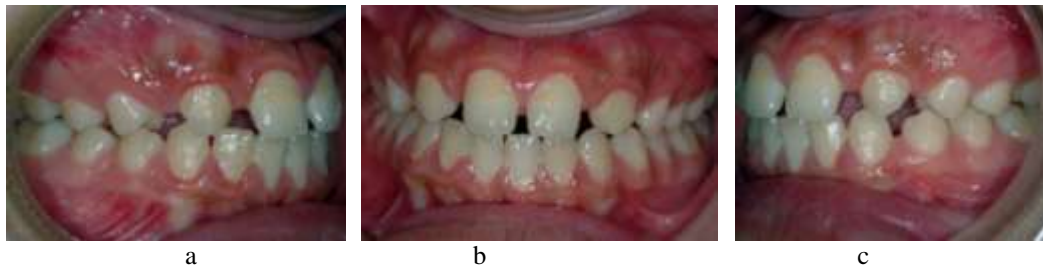

Fig.02a-c: Missing maxillary lateral incisors

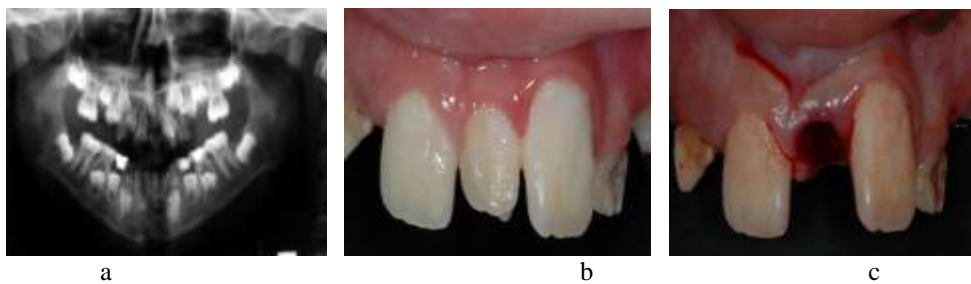

Fig.03a-c: supernumerary teeth at the midline fore extraction and after extraction

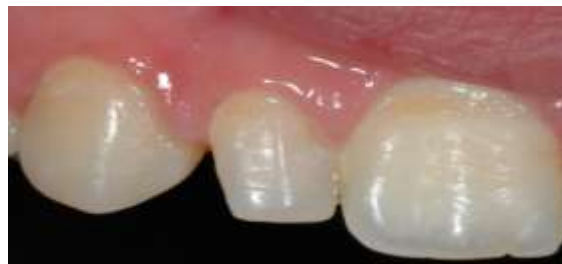

Fig.04: unusually small lateral tooth

g) Combination of imperfect fusion and congenitally missing lateral incisors (2.4%).

Other causes for the development of the maxillary midline diastema referred in literature involve:

a) rotated teeth,

b) Parafunctional oral habits, such as thumb/finger sucking or abnormal tongue posture (Fig. 05a, b),

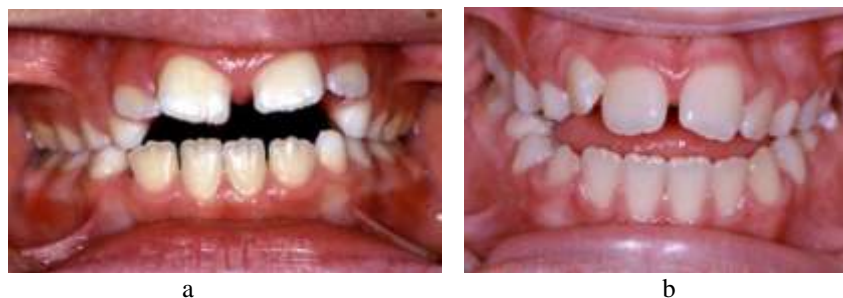

Fig.05 a, b: oral habits, thumb/finger sucking (a) or abnormal tongue posture (b)

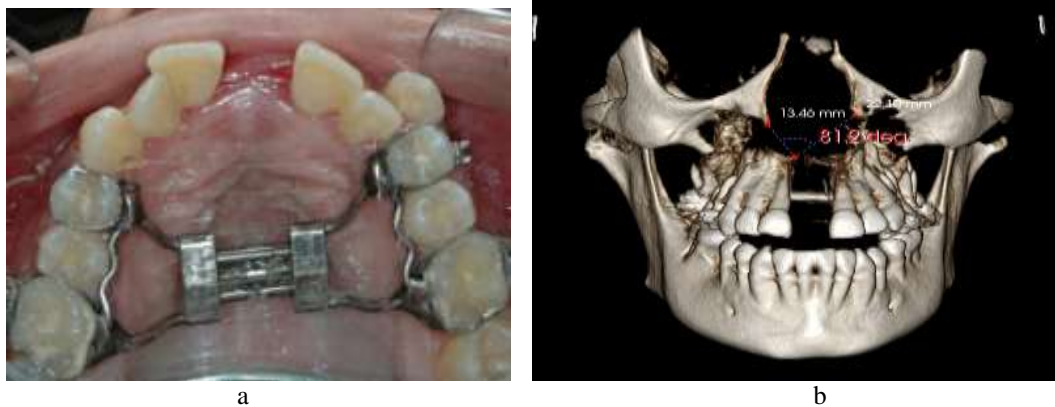

Fig.06a, b:Diastema after RPE, intraoral Foto (a), DVT (b)

- c) orthodontic treatment, as in cases of rapid palatal expansion or false teeth movement (**Fig. 06a-c**),
- d) increased anterior overbite,
- e) distal or labial inclination of maxillary central incisors
- f) generalized spacing (**Fig. 07**), and
- g) pathologic teeth migration due to periodontal disease (**Fig. 08a, b**).

Broadbent (1941) described the maxillary midline diastema in growing children as non-esthetically pleasing and characterized it as the "ugly duckling" stage of dental development. He considered this stage as a transitional phase for the maxillary interincisal diastema, indicating the space available for the erupting permanent dentition. Broadbent also described the closure of this diastema with complete eruption of lateral incisors and canines as a normal stage of occlusal development.[8]

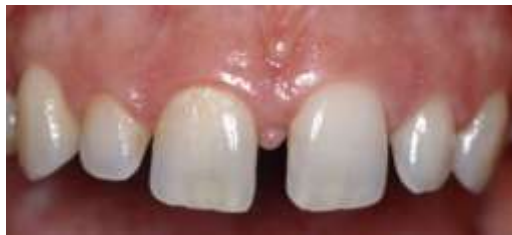

Fig.07: generalized spacing

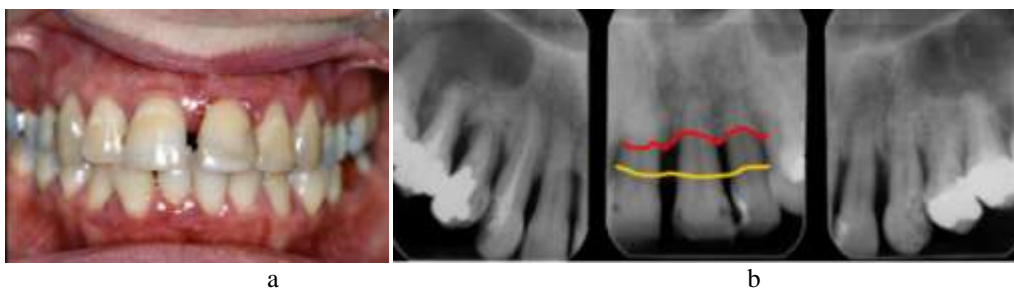


Fig. 8a, b:Development of a Diastema as a result of periodontal destruction

Based on causes, distinguish physiological and pathological diastema. As pathological diastema classifies a true diastema (diastema vera) and false diastema (diastema spuria). A different way of differentiation is provided by many researchers, who believes that true diastemata are those that increase with the growth of dental arches, and the false ones undergo reduction during the development of occlusion [5]. In the English literature, each space between the teeth is called a diastema.

Sanin et al developed a method that could predict whether the space would close spontaneously in the developing dentition. This method is based on millimeter measurements in the early mixed dentition and is claimed to have an accuracy of 88%. As the size of the diastema increases the possibility of space closure without treatment reduces.[9]

Sanin's prediction is as follows:

- For a 1 mm space in the early mixed dentition the possibility of spontaneous space closure is 99%;
- For a 1.5 mm space the possibility is 85%;

-For a 1.85 mm diastema it is 50%;-For a 2.7 mm space the possibility of closure without treatment is only 1%. The measurement should be made after the eruption of the lateral incisors. Hence it is advisable to intervene early if the midline diastema is more than 1.85 mm after the eruption of the permanent lateral incisors. [9] Numerous etiological factors contributing to the development of midline diastema have been reported and discussed in the literature. There is no agreement on a single etiological factor. The prevailing view seems to consider its development as a multifactorial phenomenon.[1,2,3,4,9]

The aim of this article is to review the possible aetiology and management options which will help the clinician to diagnose, intercept and to take effective action to correct the midline diastema. The available data shows that an early intervention is desirable in cases with large diastemas. Treatment modality, timing and retention protocol depends on the aetiology of the diastema. Therefore, priority needs to be given to diagnosing the aetiology before making any treatment decisions.

A.Prevalence Midline Diastema

Numerous studies have investigated the frequency/prevalence of diastema. Consequently, there was a wide range of findings from 1.6% to 25.4% in adults and an even greater range in groups of young people [10,11,12,13]. Differences in epidemiological study findings may be attributed to the increased number of factors contributing to midline diastema, to the definitions used to explain its presence and to gender and race differences in the distribution of the hereditary feature in question.[13]

The incidence of midline diastema varies greatly with the age group, gender, population and race. This condition is very common in the paediatric age-group at the early stages of dental development [11]. The diastema remains after the eruption of the permanent incisors and canine, such may not close on its own [1]. Oesterle and Shellhart, in 1999, reported 97% incidence in 5-year-old patients, and this decreased with age [5]. While midline diastema was found in 37% adolescent in Nigeria[14] There are divergent views on diastema. The aesthetic importance varies in relation to culture, age group and racial background. Influenced by such culture and social forms, individuals without a diastema may desire to have it created through cosmetic dentistry, while some others with diastema would rather want it closed or removed, because they find it aesthetically displeasing. [5, 6].

In Africa, maxillary midline diastema is regarded as an attractive dental feature, a sign of beauty, especially in the females, and is used as notable successful trademark[4]. Meanwhile, a study by Oboro et al in 2008 reported that majority of patients interviewed did not support the artificial creation of midline diastema [15]. The incidence of median diastema found in current study is close to that found in Kuwait (26.8%) [16]. A study among Turkish population showed that midline diastema was observed in (4.5%) of the patients and it was almost equally distributed between the females and males, 35 in females and 33 in males [17] ,whereas a study among Tanzanians found the incidence to be 26%, 11% and 8% for maxillary, mandibular, and both arches midline diastema respectively [18]. These figures were lower in these populations than in the current study. The percentage of median diastema 12.59 % is considerably higher in a study done in Pakistan [19] as compared to prevalence in United Kingdom 3.4 % of Caucasians and 1.6 % of South Indians.

The prevalence of median diastema varies in different population groups. In the earliest study, Taylor reported that the prevalence of median diastema was 7% among Californian children ranging in age of 12-18 years[20]. In two studies on Caucasian children in the United Kingdom a prevalence of 6.8% and 3.5 to 4% was reported by Weyman and Gardiner[21,22]. In a comparative study of children Horowitz reported a prevalence of median diastema of 8% for Caucasians and 19% for Negroids . In a comparative study of adults, Lavelle reported a prevalence of 3.5%, 3.4% and 5.2% for Caucasians, Mongoloids and Negroids respectively . Mc Vay and Latta studied median diastemas radiologically considering a space of more than 0.5 mm as positive for the trait[23]. They observed a prevalence of 9.6%, 12.5% and 16.3% for median diastema of 0.5 to 1.49 mm for Caucasians, Mongoloids and Negroids respectively. In the same study a prevalence of 10.4%, 7.6% and 12.9% was observed for median diastema of more than 1.5 mm for Caucasians, Mongoloids and Negroids respectively. The high prevalence for all racial groups in the above study may be due to the radiological method enabling the detection of median diastema of 0.5 mm. However, the prevalence for the Caucasian-Mongoloid groups is similar to the Negroids, being relatively higher as in the earlier studies of Horowitz and Levalle who used the direct method .[24,25]

The prevalence of the diastema in female was more than male. This result disagree with Nainar and Gnanasundaram [11] and Al-Huwaizi [26] which found that the prevalence of midline diastema in male more than female.

Genetic factors most likely play a leading role in male-female differences. Omotoso and Kadir was found that maxillary midline diastema occurs more frequently than mandibular midline diastema, and that females are more likely to have a maxillary midline diastema, while males are more likely to have a mandibular midline diastema. Diastema runs in families, and it is suggested that male children are more likely to inherit it [1,2,27].

B. Midline Diastema Etiology

Numerous etiological factors contributing to the development of midline diastema have been reported and discussed in the literature. There is no agreement on a single etiological factor[28]. The prevailing view seems to consider its development as a multifactorial phenomenon .[1,2]

To treat the midline diastema effectively, an accurate diagnosis of the aetiology and an intervention relevant to the specific aetiology is necessary. Timing of the treatment is important to achieve satisfactory results.[1,2,28] Most of the researchers do not recommend tooth movement until the eruption of the permanent canines. But in certain cases, where very large diastemas exist, treatment can be initiated early.

The following are the well established and narrated causes and treatment options for the midline diastema in the literature.

1.B-Physiological

Physiological diastemata in the definition are considered to be the manifestation of tooth replacement preparation of maxillae [2, 4] . Studies of the lack of physiological diastema in children and adolescents showed that this symptom may be an expression of inadequate physical development and requires further general diagnostics.

Most maxillary midline diastemas in the mixed dentition appear as a consequence of the growth in width of the jaws in preparation for the eruption of the larger permanent teeth. The maxillary unerupted permanent canines lie superior and distal to the apices of the lateral incisor roots, and as they erupt they tend to force the lateral and central incisors towards the midline closing the space. In most cases a diastema of less than 2mm will close spontaneously unless the patient has generalised spacing of the dentition.The incidence of diastemas varies with the age group and the race studied. Richardson and colleagues found the incidence at age 14 to be 12 per cent in white girls, 17 per cent in white boys, 19 per cent in black girls and 26 per cent in black boys[10]. Popovich and colleagues found that 83 per cent of patients with a diastema at nine years in the mixed dentition had no diastema at 16 years.[29]

Besides the physiological diastema incisors are usually fan-arranged – divergently, and because they do not look very aesthetic – this period, therefore, has been named as “ugly duckling stage”. In typically developing bite conditions the median diastema is gradually being closed during the eruption of lateral incisors and permanent canines [2, 11]. Therefore, the incidence of physiological midline diastema at age of 6 years is 98%, then it decreases to 49% at age of 11, at age of 12–18 years incidence of space between the central incisors is 7% [12].

According to Edwards [30] diastema of size not exceeding 2 mm is prone to spontaneous closure without requiring the implementation of the orthodontic appliance therapy. Bennet [31] believes that the treatment may be indicated if the child does not accept the appearance or when in the dental arch there is no space for lateral incisors. Space greater than 2 mm may require surgical intervention within the frenulum tissue [11, 14, 15]. Extreme caution should be taken when planning the closure of the diastema during the phase of bite formation. Unnecessary therapeutic intervention using removable orthodontic appliance can cause root resorption of lateral incisors, and can even stop erupting canines [16]. In some cases it is advisable to use elements of fixed orthodontic appliances in order to move and set parallelly the incisors [16]. Many authors believe that what is difficult is not the treatment for diastema closure, but the prevention of recurrence of this irregularity [11, 17].

2.B-Abnormal labial fraenum

An abnormal fraenum might be defined as one exhibiting excessive thickness and alveolar attachment between the maxillary central incisors and apparent continuity with a large incisive papilla (**Fig. 01**). A large persistent fraenum has been traditionally associated with midline diastema but the relationship between the two may have been overstated in the past. Edwards found a strong correlation between an abnormal fraenum, together with vertical osseous cleft on x-ray and the presence of a midline diastema. [30] Popovich and colleagues, however, found no such relationship.[32] Bergstrom and colleagues in a longitudinal evaluation of a group of nine year olds with abnormal fraena revealed no difference in spontaneous closure whether or not a fraenectomy had been carried out. There appears to be broad consensus, however, that when there is a v-shaped radiolucency (“notch”) in the crestal bone, on x-ray combined with a largediastema (more than 2mm), and a thick fleshy fraenum, then a fraenectomy is indicated .[33]

Popovich et al. (1977a,b) argued that in cases with diastema, the hypertrophic frenum continues to develop more coronally as the alveolar process grows with teeth eruption, because the dentition exercises minimal or no pressure on the frenum[29,32]. Tait (1924)[41] supported that the frenum has no effect on the maxillary incisors.[34]

Ceremelo (1953) concluded that the presence of the frenum is not related with the presence or the width of the midline diastema[35]. Finally, Bergstrom et al. (1973) noted that the probability of long-term spontaneous diastema closure in patients with an abnormal frenum is the same, regardless of whether or not the frenum had

been surgically excised. Consequently, further research is needed to determine the cause-effect relationship between the abnormal labial frenum and the maxillary midline diastema.[33] Miller(1985) recommended that the frenum should be characterized as pathologic when it is unusually wide or there is no apparent zone of attached gingiva along the midline or the interdental papilla shifts when the frenum is extended. However, evaluating the frenum (normal or pathologic) is sometimes rather difficult, especially in borderline cases.[36] All clinical data should be assessed in relation to patient's age, as well as to other parameters relevant to the problem.[29,32,35,36]

3.B-Missing maxillary lateral incisors

This can allow maxillary central incisors to drift distally. There are no physiological pressures placed on these teeth to close together as the canines erupt (**Fig. 02a-c**).

The diastemas due to congenital absence of lateral incisors can be treated orthodontically with closure of the diastema and proper guidance of the canines to the position of the missing lateral incisors and of the posterior teeth mesially. [33] In such cases, it is obligatory to achieve an Angle II occlusal relation. Selective grinding of the incisive and palatal canine cusps and of the palatal cusps of the first premolars and restorations with resin composite must be performed in order to transform canines and first premolars into lateral incisors and canines, respectively. This is essential for satisfying patient's esthetic requirements, as well as proper function of the stomatognathic system[1,2]. Alternative treatment options for the maxillary midline diastema caused by congenitally missing lateral incisors are to close the diastema and create the appropriate space for placing tooth-supported restorations or single-tooth implants. [34] The last options are of particular significance in cases of unilateral tooth absence, mainly because of the difficulties faced during orthodontic treatment, when trying to achieve dental arch symmetry[35]. The selection of the appropriate treatment option in cases with congenitally missing lateral incisors, depends on the present malocclusion, on the anterior teeth relationship, on the specific needs concerning the available space, on the condition of the adjacent teeth, on the tooth-size relationship and on the size and shape of the canine.[34,35,36]

The diastemas due to congenital absence of lateral incisors can be treated orthodontically with closure of the diastema and proper guidance of the canines to the position of the missing lateral incisors and of the posterior teeth mesially. In such cases, it is obligatory to achieve an Angle II occlusal relation. Selective grinding of the incisive and palatal canine cusps and of the palatal cusps of the first premolars and restorations with resin composite must be performed in order to transform canines and first premolars into lateral incisors and canines, respectively. This is essential for satisfying patient's esthetic requirements, as well as proper function of the stomatognathic system[1,2,3,4].

The last options are of particular significance in cases of unilateral tooth absence, mainly because of the difficulties faced during orthodontic treatment, when trying to achieve dental arch symmetry. The selection of the appropriate treatment option in cases with congenitally missing lateral incisors, depends on the present malocclusion, on the anterior teeth relationship, on the specific needs concerning the available space, on the condition of the adjacent teeth, on the tooth-size relationship and on the size and shape of the canine.[1,2,3,4]

4.B-Ectopic maxillary canines

The absence of the canines from their normal position can facilitate distal drift and tilt of the incisors with space opening and there is the associated lack of the physiological pressures to upright the lateral and central roots that normally closes the diastema (**Fig. 09**).

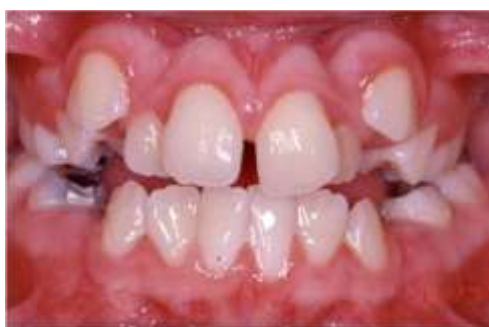

Fig.09: Development of a Diastema as a result of ectopic maxillary canine

5.B-Tooth size or shape discrepancy

The most commonly presenting of these are small lateral incisors. The Bolton Analysis may be used to compare tooth size discrepancies. This group are the most amenable to restorative and prosthetic solutions.[37]

The associated shape discrepancies most frequently seen are central incisors that are excessively triangular or have mesial surfaces that are either concave or convex (**Fig.10**).

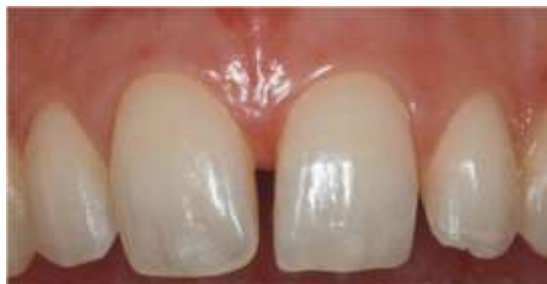

Fig.10: Diastema is associated shape discrepancies

The mesiodistal widths of the anterior teeth and the arch width should be measured. These measurements should be compared with the norms to determine whether it is contributed due to tooth size discrepancy, check whether all four incisor are small or only the lateral incisor are smaller with normal sized central incisors. Approximate mesiodistal widths of the anterior teeth and approximate arch widths, both in mm, are given in tables respectively. If only the lateral incisor is small, the Diastema should be closed orthodontically by moving the central incisor together reciprocally. Then the lateral incisor position can be corrected orthodontically and tooth size can be restored by composite build up or placement of crowns over lateral incisors.[1,2,7,14,30,38]

6.B-Mesio-distal angulation of incisors

a.Root convergence

Distally inclined incisors can produce a diastema with the tooth space positioned towards the incisal edges of the incisors[2,7]

b.Root divergence

Mesially inclined incisors can result in a coronally positioned contact point and a diastema, which is more gingivally placed. This is often referred to as the black triangle and is associated with reduced papilla infill, so that in effect it is a diastema that is closed off at its incisal aspect by contact of adjacent teeth. Burke and colleagues[39] in a study found that 40 per cent of crowded maxillary incisors can be expected to produce a black triangular space at the midline after fixed appliance treatment unless something is done to close this space before appliances are removed and the case considered finished(**Fig. 11**). There is a high incidence of concave mesial surfaces in crowded maxillary incisors, which becomes more apparent as the teeth are decrowded orthodontically (**Fig. 12**).

Tarnow and colleagues[40] in a study on the effect of the distance from the contact point to the crest of bone on the presence or absence of an interproximal dental papilla found that:

- when the distance was 5mm or less the papilla was usually present (**Fig. 13a**)
- when the distance was 6mm the papilla was present 56 per cent of the time (**Fig. 13b**); and,
- when the distance was 7mm or more the papilla was present 27 per cent of the time or less (**Fig. 13c**).

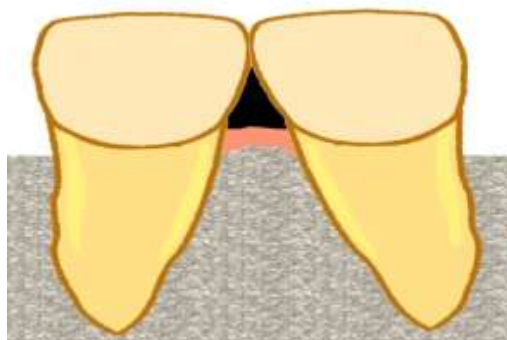


Fig.11: black triangular space ; Root divergence and mesially inclined incisors

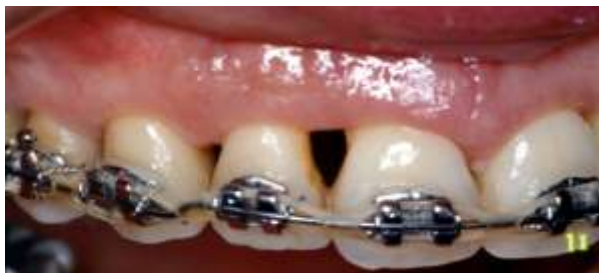

Fig.12: concave mesial surfaces in maxillary incisors after leveling

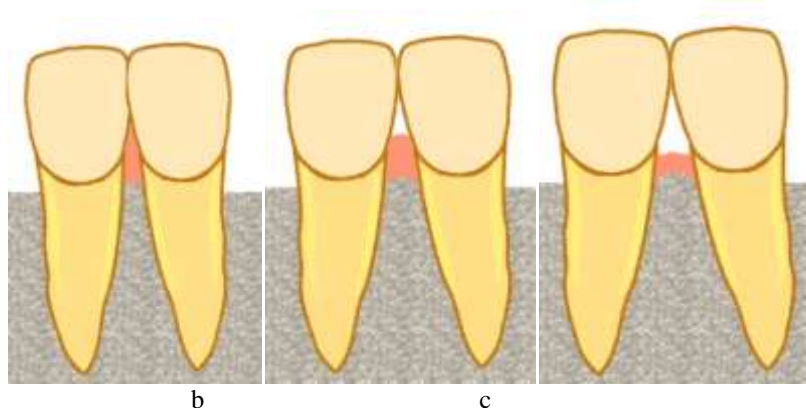


Fig.13a-c: the effect of the distance from the contact point to the crest of bone on the presence or absence of an interproximal dental papilla

7.B-Inter arch Relationship

When the combined width of the mandibular anterior teeth is very large and the combined mesiodistal width of the maxillary teeth is less, then the lower arch is well align but it does not relate with the upper arch[1,2,7]. Thus, labial positioning of the upper anterior with spacing in between upper teeth presents to match the upper arch with the well aligned lower arch. Such a case would require inter –proximal enamel reduction from lower anterior teeth or extractions of lower second premolars followed by fixed orthodontic appliances in both the arches. After the spaces are closed in the lower arch, the maxillary incisors should be retracted. This would reduce or eliminate the Diastema in the maxillary arch.[41,42]

8.B-Habits

The most frequently implicated habits are thumb, digit or soother sucking. These have a tendency to procline the maxillary labial segment, which may lead to spacing and diastema in some patients.[1,2,7,41] Oral habits such as tongue thrusting and finger sucking can be other aetiological factors for the appearance of the midline diastema.[32,33] According to Proffit and Fields, tongue position at rest may have a greater impact on tooth position than tongue pressure, as the tongue only briefly contacts the lingual surface of the anterior teeth during thrusting. The tongue pushes the anterior teeth to a forward position, increasing the circumference which results in spacing [43]. An abnormal habit of the tongue can be detected by the tip of the tongue popping out through the anterior spacing when the patient is asked to swallow. In cases of anterior open bite, the tongue may be seen thrusting between incisal edges of the maxillary and mandibular incisors. Patients with tongue thrust often produce a snap sound on swallowing and also have hyperactivity of the orbicularis oris muscle.

An abnormal tongue size is a severe problem which may create difficulties in retaining the orthodontically corrected midline diastema. Macroglossia can be detected by simple observations.[1,2,41] The patient can be asked to touch the tip of the nose with his tongue and, if he/she is able to do that, it is an indication of an extended tongue. In the same way, if tooth indentations are seen on the lateral borders of the tongue, it can be an indication of an enlarged tongue. In such cases, surgical trimming may have to be considered in order to attain stability in the dental occlusion.[35] Deleterious habits have to be corrected by using habit-breaking appliances and by psychological approaches. The use of fixed tongue cribs are found to be effective in breaking the tongue-thrusting habit.[44]

9.B-Tooth Anomalies and other Pathologic Lesions in the soft or Hard Tissues in the midline

Generally, mesiodens is present as a supernumerary tooth in the hard or soft tissue and acts as an impediment in the eruption of permanent central incisor in their correct position and also approximation of these

teeth is not possible because of its presence .again any fibrous cystic or bony lesion may also be present .radiographic assessment with intraoral periapical x-rays and upper occlusal views are recommended. Extraction of supernumerary tooth should be carried out before commencing orthodontic treatment .surgical excision in the case of pathological lesion is necessarily done and zinc oxide eugenol dressing for two weeks is placed post surgical at the site of the surgery. Orthodontic correction should follow the removal of the pathological cause.[1,2,7,41]An odontogenic keratocyst can appear in the maxilla and can displace teeth, leading to spacing in the anterior region. A median palatal cyst is another midline structure which is a rare cyst originating from the epithelium trapped along the line of fusion of the lateral palatal maxillary process during development.[41,45] Odontomas are benign odontogenic tumours composed of enamel, dentine, cementum and pulp tissue. Odontomas are the most frequent odontogenic tumours, with an incidence of 22–67% of all maxillary tumours. They are usually asymptomatic, but often associated with tooth eruption disturbances. Odontomas can be present between the roots of erupted maxillary central incisors, preventing contact between their crowns and causing large diastemas. A radiographic examination of the site will be beneficial in cases of a large diastema to rule out the presence of any midline lesions such as odontomas, when the presence of other common aetiological factors are not observed. The treatment of choice is surgical removal of the tumour and closure of the midline diastema using composites, jacket crowns or orthodontic appliances, depending on the size of the diastema . [46]

10.B-Development

A maxillary midline supernumary is a rare cause of midline diastema in children. Permanent maxillary central incisors can normally erupt with a diastema that will be reduced in size with the eruption of the lateral incisors and will completely disappear with the eruption of the canines. This happens because each permanent incisor and canine is 2-3 mm wider than its primary predecessor. Therefore, the maxillary midline diastema is frequently, not only physiologic, but necessary. If there is no pathological condition related to these specific teeth or major deviations from normal teeth size, spontaneous closure of the diastema should be considered certain in most cases. If, however, this does not happen, then intervention by the dentist may be necessary.[2,10,38,31,44]

11.B-Combinations

Not infrequently a number of the above factors combine in one patient to produce a diastema.[41]

12.B-Iatrogenic:

rapid maxillary expansion can cause midline diastema due to opening of the intermaxillary suture.[1,2,3,4,28] Moyers stated that imperfect fusion at the midline of premaxilla is the most common cause of maxillary midline diastema. The normal radiographic image of the suture is a V-shaped structure(**Fig. 6, b**).[7]

13.B-Genetic of midline diastema

The genetic nature of midline diastema International literature includes few reports on genetics or heredity as etiological factors for the development of the maxillary midline diastema.[1,2]Gardiner discusses the etiology of the persisting midline diastema and notes that there is "almost no limitation concerning contributing factors. Undoubtedly, hereditary causes are high up the list and we have all seen parents and offspring with this feature".[22]Schmitt (1982) described eight members of a family who, for more than three generations, presented a syndrome including bilateral triphalangeal thumbs, radial hypoplasia, hypospadias (congenital abnormality of the urethra) and maxillary diastema. All family members with the disease had a midline diastema and the authors concluded, on the basis of the hereditary pattern, that the syndrome follows the autosomal dominant type. The authors did not discuss the role or the correlation of the maxillary diastema with the syndrome, nor did they further elaborate on the genetic contribution possibly responsible for the expression of the dental hereditary feature.[47]

Harris and Johnson (1991) also examined the role of heredity in abnormal dental occlusion. The authors, in a longitudinal analysis of relatives, investigated both craniometric and occlusal variables. The study was based on serial evaluations of cephalometric radiographs and dental casts of 30 relatives (4 to 20 years old) with no previous orthodontic treatment from the Bolton-Brush Growth Studies in Cleveland, Ohio. The aim of the study was to evaluate the contribution of heredity to a variety of craniofacial, skeletal and occlusal variables. The authors concluded that craniometric variables are correlated with high heredity values, whereas almost all occlusal variability is more acquired and less hereditary.[48]

Neville et al. (1997) describe the thyroglossal cyst of the duct as a remnant of the thyroglossal duct epithelium that normally undergoes atrophy and is eliminated. Occasionally, however, it remains and forms a cyst. They also report that thyroglossal duct cysts appear in the midline and may develop from the foramen tongue caecum to the superior fissure. The median palatal cyst is another midline structure, which Neville et al.

describe as a rare cyst originating from epithelium trapped along the line of fusion of the lateral palatal maxillary processes during development.[45]

Nainar and Gnanasundaram (1997), in their study of midline diastemas in a South India population sample, examined 9774 individuals from 13 to 35 years of age in order to determine the consequences and possible etiological factors of this feature. The relatively increased frequency of familial occurrence led the authors to propose the presence of a genetic factor contributing to midline diastema expression.[11]

Shashua and Artun (1997) report that genetic predisposition is a probable precondition contributing to midline diastema development. The authors concluded that the family tree of diastema was one of the only two important risk factors for diastema relapse. The other factor was diastema size before treatment.[49]

Gass et al. (2003) note that preliminary results from thirty families show a possible genetic basis for this diastema. More specifically, "heritability" was estimated at 0.32 for the white and 0.04 for the black population. "Heritability" is defined as the ratio of the total genotypic diversity to the total phenotypic diversity with values ranging from 0 to 1. Data from family trees suggest a dominant autosomal hereditary type.[50]

14.B-Periodontal Status

The amount of bone support for each tooth should be of special consideration in children with juvenile periodontitis and adults with periodontal problems. Localized juvenile periodontitis is an aggressive periodontal disease, which is seen in teenagers. It is characterized by loss of tissue attachment and loss of alveolar bone around the permanent incisors and first molars. One sees a dentilabial migration of the maxillary incisors as a result of excessive bone loss forming a midline diastema. [41,51]

The first line of treatment is to control the disease by periodontal therapy like scaling, root planning and with anti-microbial agents like tetracycline and metrogyl. In most cases, consultation with a periodontitis is a must[52,53]. A close collaboration between the orthodontist and the periodontist is desirable. Ideally the treatment of juvenile periodontitis should include correction of systemic condition along with the localized measures. In advanced stages of the disease, it is difficult to retain the teeth in function but in early stages, the disease can be eliminated and the dentition can be retained. The only contraindication to orthodontic treatment for this persistence of gingival inflammation and severe bone loss in spite of adequate phase I periodontal therapy, which includes preparation of tooth surface, plaque control, antimicrobial agents, and control of uncomplicated gingivitis. In adult seeking orthodontic closure of anterior spacing, it is assumed that bone remodeling process may occur more slowly. So, for both teenagers with initial stages of localized juvenile periodontitis and adult with or without periodontal problems, phase I periodontal therapy procedures are finished first, preferably by a periodontist. Orthodontic treatment should be started only after the inflammation of the gingival has reduced to a minimum by the phase I periodontal therapy. [51,53,54,55]

Major occlusal adjustments and periodontal surgical procedures are performed after completion of orthodontic space closure as firstly, orthodontics may change the shape of periodontium reducing the extend of surgery and secondly, the removal of supracrestal fibers during surgery will facilitate retention. Generally to correct pathologic tooth migrations of anterior teeth, a tissue borne removable appliance with a labial wire or light elastic attached to the hooks embedded in the acrylic at the distal surface of each canine is used[54,55]. These elastics are engaged below the brackets or buttons on the incisors. this would produce light and intermittent forces that would intrude as well as retract the anterior teeth closing the diastema .these light and intermittent forces are ideal for the closure of diastemas created by pathologic migration of anterior teeth .in adult patients, when there is loss of periodontal attachment, surface area of supported root becomes smaller and the center of resistance also becomes further. So, for tooth movement light forces with relatively large moments are needed.[1,2,3,55]

C.TREATMENT OPTIONS

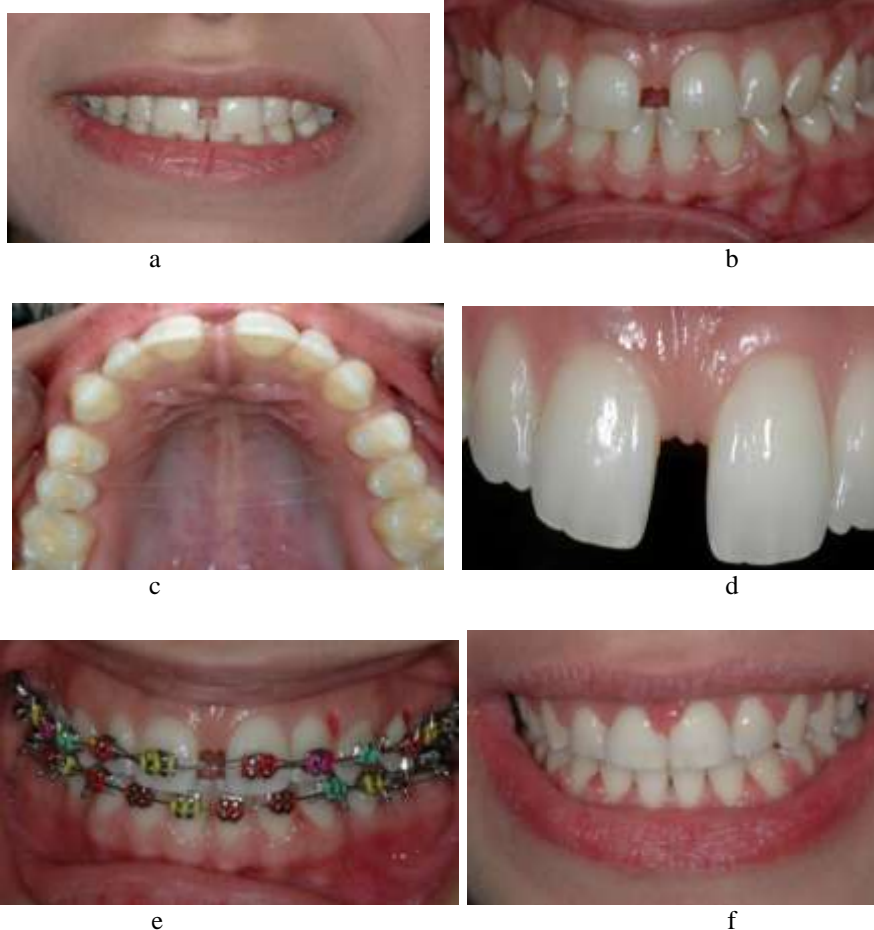A major problem for the dentist in dealing with the midline diastema is the decision to intervene or not to intervene during the early mixed dentition period. As it is widely stated and presumed that the midline diastema during the 'ugly duckling stage' is a normal phenomenon and is self-correcting, it is tempting for the dentist to suggest to the parents of the child to wait until the permanent canines erupt.[1,2,3,4,28] Before the practitioner can determine the optimal treatment, he or she must consider the contributing factors. These include normal growth and development, tooth size discrepancies, excessive incisor vertical overlap of different causes, mesiodistal and labiolingual incisor angulation, generalized spacing and pathological conditions. A carefully developed differential diagnosis allows the practitioner to choose the most effective orthodontic and/or restorative treatment. Diastemas based on tooth-size discrepancy are most amenable to restorative and prosthetic solutions. The most appropriate treatment often requires orthodontically closing the midline diastema. Treatment of diastema varies and it requires correct diagnosis of its etiology, and early intervention relevant to the specific etiology. **Correct diagnoses include radiological and clinical examinations and possibly tooth size evaluation.**[2,3,4]

- No treatment is usually done, if the diastema is physiological/transient as it spontaneously closes after the eruption of permanent maxillary canines. Spontaneous correction of a childhood diastema is most likely when its width is not more than 2mm.
- Pathological causes like supernumerary teeth, midline soft tissue anomalies can be removed surgically and spaces are closed orthodontically. Oral habits such as thumb sucking and tongue thrusting should be corrected before closure of the space.

A.Orthodontic Approach:

It is an error to surgically remove the frenum at an early age and then delay orthodontic treatment in the hope that the diastema will close spontaneously. If the frenum is removed, while there is still a space between the central incisors, scar tissue forms between the teeth as healing progresses, and a long delay may result in a space that is more difficult to close than it was previously.[56,57,58]

It is better to align the teeth before frenectomy. Sliding them together along an arch wire is usually better than using a closing loop, because loop with any vertical height will touch and irritate the frenum. If the diastema is small, it is usually possible to bring the central incisors completely together before surgery.If the space is large and frenal attachment is thick, it may not possible to completely close the space before surgical intervention. The space should be closed at least partially and the orthodontic movement to bring the teeth together should be resumed immediately after the frenectomy, so that the teeth are brought together quickly after the procedure. When this is done, healing occurs with the teeth together and the inevitable post-surgical scar tissue stabilizes the teeth instead of creating obstacles to final closure of the space.[1,2,3,4,28] (Fig 14 a-h)



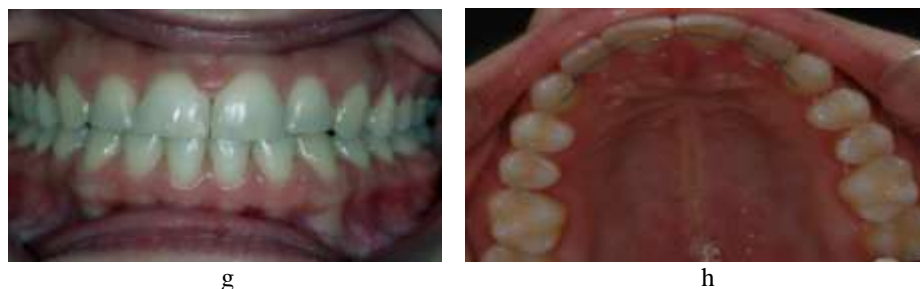

Fig.: 14a-h:
a-e: Case treated by using SWA: pre-treatment before the frenectomy
f-h: post-treatment with permanent bonded retainer

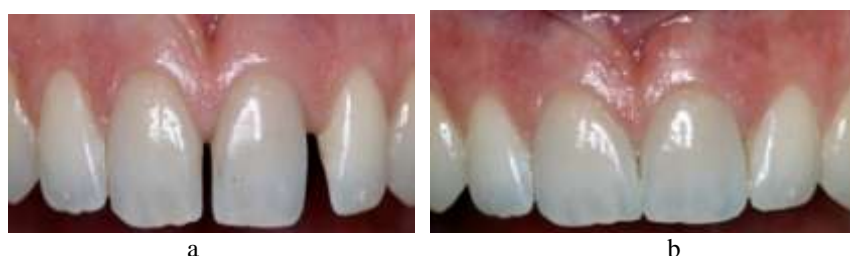

Fig.15 a, b:Aesthetic approach: after the orthodontic treatment (a) the case treated with restorative material (b)

A study by Kerosuo (1995) reports that people with significant anterior crowding or midline diastema were very frequently considered less intelligent, beautiful and sexually attractive and were perceived to be of a lower social status in comparison to the same individuals when they had excellent occlusion.[59] Rosenstiel and Rashid (2002), in an Internet study concerning the opinion of laypeople about anterior teeth esthetics, showed that conditions such as diastema and midline deviation received the worst ratings. Detailed analysis and understanding of malocclusion is needed by the orthodontist, so that s/he may successfully treat midline diastema for the patients esthetic and functional benefit.[60] According to Attia (1993), if the diastema is due to a mesiodens, the latter should be extracted and orthodontic treatment should follow immediately in order to achieve a stable result. If the diastema is due to congenital absence of a lateral incisor, there are two options following midline diastema closure: mesial canine movement to the lateral incisor position or distal canine movement and prosthetic restoration of missing lateral incisors (with or without osseointegrated implants) [61]. If the reason for the diastema is peg-shaped laterals (one or both), then, following space closure between central incisors and with great respect for the midline, the space necessary for the prosthetic restoration of peg laterals is created. If the diastema is due to hypertrophic frenum, the latter should be surgically excised after space closure [61,62]. Edwards (1977) describes the surgical technique for frenum excision preserving the interdental papilla and removing fibrous bundles and interseptal fibers.[30] Sullivan et al. (1996) examined a sample of 35 patients, with maxillary canines already erupted, presenting diastema ranging from 0.9 to 3 mm. The aim of the study was to evaluate the stability of diastema closure following the period of retainer use, to investigate any relapse signs and to examine the relationship between relapse and post-retention changes. The authors found that measurable relapse of diastema was evident in 12 out of 35 cases.[13] Shashua and Artun (1999)[49], in their study of 96 patients who were treated orthodontically and had a midline diastema ranging from 0.5 to 5.62 mm, came up with findings similar to those of Sullivan et al. (1996). The authors found a relapse rate of 49% and concluded that the only relapse risk factors were pre-treatment diastema size and presence of one family member with a similar condition.[13,49]

A bonded palatal fixed retainer is advisable in the majority of cases to stabilise the result post treatment. In wider diastemas this retention should be permanent. As with all bonded retainers patients should be instructed in good oral hygiene, including the use of floss threaders.[63,64,65]. The authors generally provide patients who have bonded retainers with a removable Hawley-type retainer to be worn at night for the first few years. Mulligan in a recent report presents a novel method of reducing retention requirements in these cases. He moves the apices of the incisors distally in finishing the treatment[64]. In this way, he postulates, larger functional moments are produced when the incisor roots are divergent which help to keep the diastema closed. To test the stability he removed the archwires for a six-week period near the end of treatment. The disto-incisal edges of the tipped teeth are modified with the use of disks for enhanced aesthetics. This interesting approach holds promise.[7,63,65]

B. Esthetic Approach;

1.b. Laboratory Analysis: A functional analysis would need to be done in the diagnostic wax-up, and eventually the provisional prototypes, to make sure that the new restorations would be compatible with habitual movements such as those that occur in mastication and speech. The steepness of the interarch relationship in the area of the cuspids (along with the type of food) determines to a large degree the path of closure during mastication.[1,2,3,4]

The completed laboratory analysis via the diagnostic equilibration and wax-up provide a great deal of information:

a. The number of restorative units needed to optimally eliminate the patient's dental midline diastema .[1,2]

b. The wax-up illustrated how the individual restorations would appear dimensionally and whether an occlusal/functional scheme could be worked out that would provide proper force management for longevity of the restorations.[1,2]

c. The wax-up would serve as the prototype design for the direct fabrication of the provisional restorations so that laboratory approximations could be adjusted and verified in vivo.[1,2]

2.b. Restorative treatment

Patient demand for aesthetic dentistry with minimally invasive procedures has resulted in the extensive utilization of freehand bonding of composite resin to anterior teeth .[1,2,3,4]

Dental patients are more conscious of their appearances and have raised the importance of the smile within society as a whole; this impacts full mouth restoration as well as more conservative restorative procedures that include class IV restorations, veneers and diastema closure.[2]

The diastema presents itself to the dental office on a regular basis. It may be small or large. The papilla may be long and skinny or blunted. The size will have an effect on what material will be chosen to achieve the desired results. When dealing with a large space closure, orthodontist may be indicated to allow for a more esthetic outcome.[1,2]

When the teeth are in proper orthodontic alignment, no preparation of the tooth structure is necessary. If there is an alignment problem, minor tooth preparation will be necessary to achieve proper arch form.

Composite resin is an ideal material when restoring diastema closure. It is highly polishable, long lasting and mimics natural tooth structure. It is a conservative alternative to an indirect restoration [1,2] (**Fig 14 a, b**).

It is important to mention that there are restorative solutions to these cases without orthodontic intervention.[41,53] However, restorative measures are more likely to be appropriate in adults and are also subject to on-going maintenance issues. Care must be taken that the emergence profile of any restoration is not over-contoured creating hygiene problems. Care must also be taken with the crown width/length ratio.[56,58]

Maxillary midline spacing can also be reduced or temporarily closed with composite resin directly on the proximal surfaces of teeth adjacent to the space without bonding agent prior to orthodontics. It may then be removed as tooth movement proceeds. When combined orthodontic-restorative treatment is planned, collaboration between the orthodontist and the restoring dentist should begin at the diagnostic phase.[1,2,3,4,28]

1. Conclusion

The etiology of midline diastema is a very important factor that has to be taken into consideration before starting any orthodontic correction. Environmental factors as well genetic influences together play a vital role in the etiology of midline diastema hence the orthodontist role to evaluate the various important factors and predict the risk of a developing midline diastema in future generation is valuable for patient diagnosis, treatment and retention. However, if the diastema is more than 1.8 mm, even after the eruption of lateral incisors, an orthodontic intervention will be necessary. A radiographic examination of the site will be beneficial to rule out any multifactorial aetiology. To achieve an aesthetic and stable result, it is important to establish the underlying cause for the midline diastema. Retention protocol should depend on the size and the aetiology of the midline diastema.

References

- [1]. Azzaldeen A, Muhamad AH. Diastema Closure with Direct Composite: Architectural Gingival Contouring. J Adv Med Dent Sci Res 2015;3(1):134-139
- [2]. Abu-Hussein M ,Watted N ,Abdulgani A ;An Interdisciplinary Approach for Improved Esthetic Results in the Anterior Maxilla Diastema Journal of Dental and Medical Sciences 2015,14(12), 96-101
- [3]. Abu-Hussein M , Abdulgani A , Watted N Zahalka M ; Congenitally Missing Lateral Incisor with Orthodontics, Bone Grafting and Single-Tooth Implant: A Case Report. Journal of Dental and Medical Sciences 2015 , 14(4),124-130
- [4]. Abdulgani A ,Watted N ,Abu-Hussein M DIRECT BONDING IN DIASTEMA CLOSURE HIGH DRAMA, IMMEDIATE RESOLUTION: A CASE REPORT.IJDHS2014.1(4):430-435

- [5]. 5.Angle EH. In: Angle . Treatment of malocclusion of the teeth, 7th edition. Philadelphia: S.S. White Dental Manufacturing Co., 1907:167.
- [6]. 6.Andrews LF. The six keys to normal occlusion. Am J Orthod 1972;62:296-309.
- [7]. 7.Moyers R. Handbook of Orthodontics. 4th ed. Year Book Medical Publishers, Chicago, USA, 1988, 348–360
- [8]. 8.Broadbent BH. Ontogenic development of occlusion. Angle Orthod, 1941;11: 223-241.
- [9]. 9.Sanin C, Sekiguchi T, Savara BS. A clinical method for the prediction of closure of the central diastema. ASDC J Dent Child 1969; 36: 415–418.
- [10]. 10.Richardson ER, Malhotra SK, Henry M, Little RG, Coleman HT. Biracial study of the maxillary midline diastema. Angle Orthod 1973;43:438-43.
- [11]. 11.Nainar SM, Gnanasundaram N. Incidence and etiology of midline diastema in a population in south India (Madras). Angle Orthod 1989;59:277-82
- [12]. 12.Steigman S, Weissberg Y. Spaced dentition. An epidemiologic study. Angle Orthod 1985;55:167-76.
- [13]. 13.Sullivan TC, Turpin DL, Artun J. A postretention study of patients presenting with a maxillary median diastema. Angle Orthod 1996;66:131-8.
- [14]. 14.Oesterle LJ and Shellhart WC. Maxillary midline diastema: a look at the causes. Journal of American Dental Association 1999;130:85-94.
- [15]. 15.Oboro HO, Umanah AU, Chukwumah NM, Sede M . Creation of artificial midline maxillary diastema: opinion of Nigerian dentists. (online) 2008 (cited 2009 Nov 16)
- [16]. 16.S. Al Enezi1 - Dr. E Zaatar1 - Dr. N O Salako2. Prevalence of Selected Dental Anomalies in Kuwaiti Orthodontic Patients.orthodontics journal; DENTAL NEWS2002, 9(4), 23-31
- [17]. 17.MevlutCelikoglu 1, SemaAkpınar 1, Ibrahim Yavuz 2 The pattern of malocclusion in a sample of orthodontic patients from Turkey.Journal section: Clinical and Experimental Dentistry doi:10.4317/medora.15.e791
- [18]. 18.Athumani AP and Mugonzibwa EA. Perception on diastema medially among dental patients attending Muhimbili National Hospital. Tanzania Dental Journal 2006;12 (2)50-57.
- [19]. 19. HamedullahJan ,Sadia Naureen, AyeshaAnwar: Frequency and etiology of midline diastema in orthodontic patients reporting to armed forces institute of dentistry Rawalpindi Pakistan: Armed Force Medical Journal 2010;1,4-10
- [20]. 20. Taylor JE. Clinical observations relating to the normal and abnormal frenum labii superiors. American Journal of Orthodontics 1939; 25:646.
- [21]. 21. Weyman J. The incidence of median diastema during the eruption of the permanent teeth. The Dental Practitioner 1967; 17:276-278.
- [22]. 22. Gardiner JH. Midline spaces. The Dental Practitioner 1967; 17:287-297.
- [23]. 23. McVay TJ, Latta GH, Jr. Incidence of the maxillary midline diastema in adults. J Prosthet Dent 1984;52:809-11.
- [24]. 24 Horowitz HS. A study of occlusal relations in 12 year old Caucasian and Negroid children. International Dental Journal 1970: 20:593-597.
- [25]. 25. Lavelle CLB. The distribution of diastemas in different human population samples. Scandinavian Journal of Dental Research 1970; 78: 530-534.
- [26]. 26.Al-Huwaizi AF, Al-Alousi WS, Al-Mulla AA. The dental midline at 13 year of age. J Coll Dentistry 2003; 15: 1-7.
- [27]. 27.Omotoso GO, Kadir E.: Midline Diastema Amongst South-Western Nigerians. The Internet J Dental Science. 2010; 8(2).432-339
- [28]. 28.Abu-Hussein M., Watted N., Abdulgani A., and Bajali M.; Treatment of Patients With Congenitally Missing Lateral Incisors: Is an Interdisciplinary Task.RRJDS 2014,2(4),53-68
- [29]. 29.Popovich F, Thompson GW, Main PA. Persisting maxillary diastema: differential diagnosis and treatment. Dent J 1977b;43:330-3.
- [30]. 30. Edwards J.G.: The diastema, the frenum, the frenectomy. Am. J. Orthod. 1977, 71, 489–508.
- [31]. 31.Bennet J.C., McLaughlin R.P.: Fixed appliances. Orthodontic treatment with straight-wire technique. Czelej, Lublin1999, p. 77
- [32]. 32.Popovich F, Thompson GW, Main PA. The maxillary interincisal diastema and its relationship to the superior labial frenum and intermaxillary suture. Angle Orthod 1977a;47:265-71.
- [33]. 33.Bergstrom K, Jensen R, Martensson B. The effect of superior labial frenectomy in cases with midline diastema. Am J Orthod 1973;63:633-8.
- [34]. 34.Tait CW. The median frenum of the upper lip and its influence on the spacing of the upper central incisor teeth. Dent Cosmos1924, 76: 991–992
- [35]. 35.Ceremelo PJ. The superior labial frenum and the midline diastema and their relation to growth and development of the oral structures. Am J Orthod, 39: 120–139, 1953.
- [36]. 36.Miller PD Jr. The frenectomy combined with a laterally positioned pedicle graft. Functional and esthetic considerations. J Periodontol, 56: 102–106, 1985.
- [37]. 37.Bolton WA. Clinical application of a tooth – Size analysis. Am. J. Orthod. 1962; 61: 504-529.
- [38]. 38.Bishara, S.E.; Management of diastema in orthodontics Am.J.Orthod. 61:55-63, 1972.
- [39]. 39.Burke S, Burch JG, Tetz JA. Incidence and size of pretreatment overlap and posttreatment gingival embrasure space between maxillary central incisors. Am.J.Orthod. Dentofacial Orthop. 1994; 105(5): 506-511.
- [40]. 40. Tarnow DP, Magner AW, Fletcher P. The effect of the distance from the contact point to the crest of bone on the presence or absence of the interproximal dental papilla. J. Periodontol.1992; 63 (12): 995-996.
- [41]. 41.Gkantidis N, Kolokithao,Topouzelis N. Management of maxillary midline diastema with emphasis on etiology. Pediatr Dent. 2008; 32(4): 265272.
- [42]. 42.Alexandros T.Moullas; Maxillary midline Diastema: a contemporary review: Hellenic Orthodontic review 2005,18(2) , 93-103
- [43]. 43.Proffit WR, Fields HW. Contemporary Orthodontics 2nd edn. St Louis: Mosby Yearbook, 1993: 467.
- [44]. 44.McVay TJ, Latta GH Jr. Incidence of the maxillary midline diastema in adults. J Prosthet Dent 1984; 52: 809–811
- [45]. 45. Neville BW, Damm DD, Brock T. Odontogenic keratocysts of the midline maxillary region. J OralMaxillofac Surg 1997;55:340-4.
- [46]. 46.Serra GS, Aytes LB, Escoda CG. Erupted odontomas: a case report of threecases and review of literature. MedOral Patol Oral Cir Bucal 2009; 14: 299–303.

- [50]. 47.Schmitt E, Gillenwater JY, Kelly TE. An autosomal dominant syndrome of radial hypoplasia, triphalangeal thumbs, hypospadias, and maxillary diastema. *Am J Med Genet* 1982; **13**: 63–69.
- [51]. 48.Harris EF, Johnson MG. Heritability of craniometric and occlusal variables: a longitudinal sib analysis. *Am J Orthod Dentofacial Orthop* 1991;99:258-68.
- [52]. 49. Shashua D, Artun J. Relapse after orthodontic correction of maxillary median diastema: a follow-up evaluation of consecutive cases. *Angle Orthod* 1999;69:257-63.
- [53]. 50. Gass JR, Valiathan M, Tiwari HK, Hans MG, Elston RC. Familial correlations and heritability of maxillary midline diastema. *Am J Orthod Dentofacial Orthop* 2003;123:35-9.
- [54]. 51.Gkantidis N, Christou P, Topouzelis N. The orthodontic–periodontic interrelationship in integrated treatment challenges: a systematic review. *J Oral Rehabilitation* 2010;37:377-390.
- [55]. 52.Lindhe J. Textbook of clinical periodontology. 2nd ed. Copenhagen: Munksgaard;
- [56]. 1989.
- [57]. 53.Spear FM, Kokich VG, Mathews DP. Interdisciplinary management of anterior dental esthetics. *J Am Dent Assoc* 2006;137:160–169.
- [58]. 54.Van Gastel J, Quiryneen M, Teughels W, Coucke W, Carels C. Longitudinal changes in microbiology and clinical periodontal parameters after removal of fixed orthodontic appliances. *Eur J Orthod* 2011;33:15-21.
- [59]. 55. Reitan K. Biomechanical principles and reactions. In: Graber X, Swain BF, editors. *Current orthodontic concepts and techniques*. St Louis: CV Mosby; 1985. p. 101-92.
- [60]. 56.Kokich VO Jr, Kinzer GA. Managing congenitally missing lateral incisors. Part I: Canine substitution. *J Esthet Restor Dent* 2005t, 17: 5–10,
- [61]. 57. Kinzer GA, Kokich VO Jr. Managing congenitally missing lateral incisors. Part II: tooth-supported restorations. *J Esthet Restor Dent* 2005a, 17: 76–84
- [62]. 58. Kinzer GA, Kokich VO Jr Managing congenitally missing lateral incisors. Part III: single-tooth implants. *J Esthet Restor Dent* 2005b, 17: 202–210
- [63]. 59.Kerosuo H, Hausen H, Laine T, Shaw WC. The influence of incisal malocclusion on the social attractiveness of young adults in Finland. *Eur J Orthod* 1995;17:505-12.
- [64]. 60 . Rosenstiel SF, Rashid RG. Public preferences for anterior tooth variations: a web-based study. *J Esthet Restor Dent* 2002;14:97-106
- [65]. 61.Attia Y. Midline diastemas: closure and stability. *Angle Orthod* 1993;63:209-12.
- [66]. 62.Sakellarios P. Treatment of diastema between the central maxillary incisors by early excision of the labial frenum]. *Odontostomatol Proodos* 1973;27:233-9.
- [67]. 63.Zachrisson, B. Important aspects of long-term stability. *J Clin Orthod* 1997;31:562-83.
- [68]. 64.Mulligan TF. Diastema closure and long-term stability. *J Clin Orthod*
- [69]. 2003; **37**(10): 560–574.
- [70]. 65. Graber L.W., Vanarsdall R.L. Jr., Vig K.W.L.: *Orthodontics – current principles and techniques*. Elsevier & Mosby, Philadelphia 2012, 5th ed.